



## Collaborative Review – Prostate Cancer

# Can Clinically Significant Prostate Cancer Be Detected with Multiparametric Magnetic Resonance Imaging? A Systematic Review of the Literature

Jurgen J. Fütterer<sup>a,\*</sup>, Alberto Briganti<sup>b</sup>, Pieter De Visschere<sup>c</sup>, Mark Emberton<sup>d</sup>, Gianluca Giannarini<sup>e</sup>, Alex Kirkham<sup>f</sup>, Samir S. Taneja<sup>g</sup>, Harriet Thoeny<sup>h</sup>, Geert Villeirs<sup>c</sup>, Arnauld Villers<sup>i</sup>

<sup>a</sup> Radboud University Nijmegen Medical Centre, Nijmegen, The Netherlands; <sup>b</sup> Division of Oncology/Unit of Urology, Urological Research Institute, IRCCS Ospedale San Raffaele, Milan, Italy; <sup>c</sup> Department of Radiology, Ghent University Hospital, Ghent, Belgium; <sup>d</sup> Research Department of Urology, University College London, London, UK; <sup>e</sup> Urology Unit, Academic Medical Centre Hospital “Santa Maria della Misericordia”, Udine, Italy; <sup>f</sup> Department of Radiology, University College London Hospital, London, UK; <sup>g</sup> Division of Urologic Oncology, Department of Urology, NYU Langone Medical Center, New York, NY, USA; <sup>h</sup> Department of Radiology, Neuroradiology and Nuclear Medicine, University of Bern, Inselspital, Bern, Switzerland; <sup>i</sup> Department of Urology, Lille University Medical Centre, University Lille Nord de France, Lille, France

### Article info

#### Article history:

Accepted January 13, 2015

#### Keywords:

Prostate cancer  
Systematic review  
Multiparametric MRI

### Abstract

**Context:** Detection of clinically significant prostate cancer (PCa) is a major challenge. It has been shown that multiparametric magnetic resonance imaging (mpMRI) facilitates localisation of PCa and can help in targeting prostate biopsy.

**Objective:** To systematically review the literature to determine the diagnostic accuracy of mpMRI in the detection of clinically significant PCa.

**Evidence acquisition:** The Pubmed, Embase, and Cochrane Central Register of Controlled Trials (CENTRAL) databases were searched from January 1, 2000 to September 30, 2014, using the search criteria “prostate OR Pca OR PSA OR prostatic OR prostate cancer” AND “MR OR NMR OR NMRI OR MRI OR magnetic resonance OR ADC OR DWI OR DCE OR diffusion weighted OR dynamic contrast OR multiparametric OR MRSI OR MR spectroscopy”. Two reviewers independently assessed 1729 records. Two independent reviewers assessed the methodologic quality using the Quality Assessment of Diagnostic Accuracy Studies (QUADAS-2) 2 tool.

**Evidence synthesis:** Twelve articles were eventually selected. Patients had a median age of 62–65 yr (range 39–83 yr), a median prostate-specific antigen (PSA) level of 5.1–13.4 ng/ml (range 1.2–228 ng/ml), and Gleason score of 6–10. Various definitions of clinical significance were used, mainly based on maximum cancer core length and grade at biopsy, number of positive cores, and PSA. Detection of clinically significant PCa using mpMRI ranged from 44% to 87% in biopsy-naïve males and men with prior negative biopsies using prostate biopsy or definitive pathology of a radical prostatectomy specimen as the reference standard. The negative predictive value for exclusion of significant disease ranged from 63% to 98%.

**Conclusions:** mpMRI is able to detect significant PCa in biopsy-naïve males and men with prior negative biopsies. The negative predictive value of mpMRI is important to the clinician because mpMRI could be used to rule out significant disease. This may result in fewer or no systematic or targeted biopsies in patients with PSA suspicious for prostate cancer.

**Patient summary:** We reviewed the diagnostic accuracy of multiparametric magnetic resonance imaging (mpMRI) for the detection of clinically significant prostate cancer (PCa). We conclude that mpMRI is able to detect significant PCa and may be used to target prostate biopsies.

© 2015 European Association of Urology. Published by Elsevier B.V. All rights reserved.

\* Corresponding author. Radboud University Nijmegen Medical Centre, Geert Grooteplein 10, Nijmegen, 6500 HB, The Netherlands. Tel. +31 243614545; Fax: +31 243614545. E-mail address: [jurgen.futterer@radboudumc.nl](mailto:jurgen.futterer@radboudumc.nl) (J.J. Fütterer).

## 1. Introduction

A major concern related to prostate cancer (PCa) screening and early detection is overdiagnosis and overtreatment of indolent disease. Strategies to reduce overdiagnosis are necessary, as are strategies to differentiate indolent from aggressive tumours [1].

The conventional diagnostic pathway in men with elevated serum prostate-specific antigen (PSA) levels and/or abnormal digital rectal examination consists of a random systematic transrectal ultrasound (TRUS)-guided prostate biopsy (PB) [2]. The main disadvantages are that (1) TRUS-guided PB misses a substantial proportion of significant PCa (approx. 20%) because of sampling errors, especially in the anterior part of the prostate gland [3,4], and (2) a high proportion of men are diagnosed with clinically insignificant disease, which may result in subsequent overtreatment.

Owing to its high soft-tissue contrast, high resolution, and ability to simultaneously image functional parameters, magnetic resonance imaging (MRI) provides the best visualisation of the prostate compared to other imaging methods. Over the past years, MRI use has shifted from staging purposes to detection and tumour localisation. PB based on MRI findings improves PCa detection over systematic TRUS-guided PB [5]. Functional techniques, such as diffusion-weighted MRI (DW-MRI), dynamic contrast-enhanced MRI (DCE-MRI), and/or MR spectroscopy imaging (MRSI) [6–10], in addition to conventional T2-weighted anatomical sequences (multiparametric MRI, mpMRI), have resulted in accurate PCa localisation [11–14] and allow image-guided targeted sampling to overcome the limitations of the traditional blind PB.

mpMRI detects both high-grade and larger tumours accurately, which means it may perform particularly well for detection of clinically significant disease [10]. Evidence is being gathered to identify cancers of significant volume. Moreover, these functional techniques may be used to differentiate between low- and intermediate/high-grade PCa [15–18]. These characteristics make MRI a potential tool for ruling out significant disease. The next step that will be taken is to identify cancers of significant grade (Gleason 4 or 5 component) independent of the volume. DW-MRI is the most promising technique for investigating not only tumour size but also aggressiveness [16].

The aim of the present study was to perform a systematic review of the literature to determine the diagnostic accuracy of mpMRI for the detection of clinically significant PCa.

## 2. Evidence acquisition

### 2.1. Search strategy

A literature search using the Medline and Embase databases, Cochrane reviews, and the Cochrane database of clinical trials was performed. The following inclusion criteria were used: humans; male gender; adult; English language and publication date from January 1, 2000 until September 30, 2014. The

search terms used were “prostate OR PCa OR PSA OR prostatic OR prostate cancer” AND “MR OR NMR OR NMRI OR MRI OR magnetic resonance OR ADC OR DWI OR DCE OR diffusion weighted OR dynamic contrast OR multiparametric OR MRSI OR MR spectroscopy”. Abstracts were reviewed for relevance to the defined review question. If it was not clear from the abstract whether the paper might contain relevant data, the full paper was assessed. Other significant studies cited in the reference lists of the selected papers were evaluated, as were studies published after the systematic search. Moreover, reports from meetings were also considered, but review articles and editorials were excluded from the analysis. The systematic review was performed according to the Preferred Reporting Items for Systematic Reviews and Meta-analyses (PRISMA) guidelines [19].

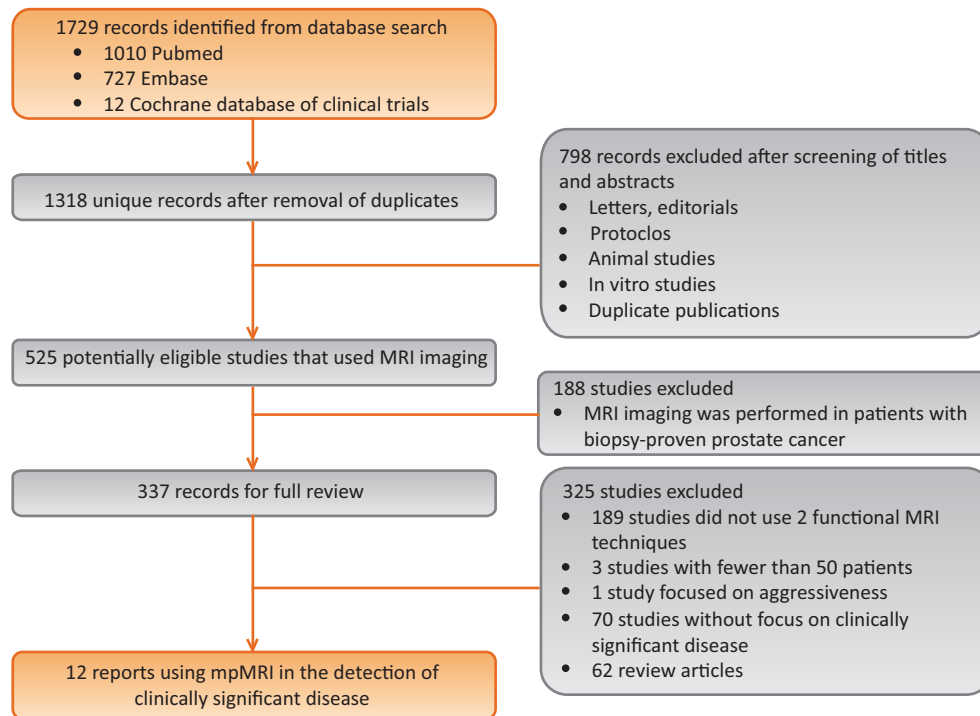
### 2.2. Study selection

We screened all retrieved records and included studies in which prostate MRI was performed with at least two functional MRI techniques (DW-MRI, DCE-MRI, or MRSI) in addition to anatomical T2-weighted MRI to detect clinically significant PCa, with PB or definitive pathology of a radical prostatectomy (RP) specimen as the reference standard. We excluded studies with a sample size of less than 50 patients. Two reviewers performed the first screening of titles and abstracts to select eligible studies, and then independently evaluated the records. Quality assessment of the included studies was performed by two independent reviewers using the Quality Assessment of Diagnostic Accuracy Studies (QUADAS-2) tool for diagnostic accuracy studies [20]. Inter-reviewer agreement was assessed using the Cohen *k* coefficient. Any disagreement was discussed and resolved by consensus. A flowchart showing the numbers of papers identified and included or excluded at each stage is presented in Figure 1.

### 2.3. Data extraction

A standardised form was used to extract data on patient characteristics, technical characteristics of the MRI equipment and imaging protocols, definitions of clinically significant disease, and methodologic characteristics.

The following data were extracted: year of publication, number of patients, patient age, PSA level, Gleason score, previous prostate biopsies, field strength, MRI vendor, use of phased array coils, use of endorectal coils, lesions per patient, MRI sequence(s) used to define the target, T2-weighted acquisition parameters, DW-MRI acquisition parameters, DCE-MRI acquisition parameters, information on prior PB, reference standard (cognitive or MRI/TRUS fusion transrectal PB, transperineal template prostate mapping, or definitive pathology of RP specimens), patient enrolment, study design, blinding, region of interest (whole gland, index lesion, or sectors), scoring of mpMRI data, MRI criteria for PB, overall detection rate, and definition of clinically significant disease. The standards of reporting for MRI-targeted biopsy (START) criteria were used for data extraction [21].



**Fig. 1 – Flow diagram of the process used to select studies for systematic review. We systematically searched Pubmed, Embase, and the Cochrane database of clinical trials. MRI = magnetic resonance imaging; mpMRI = multiparametric MRI.**

#### 2.4. Definition of clinically significant disease

Currently, there is no universally accepted definition of clinically significant disease, either at PB or at definitive pathology after RP. To overcome this limitation, one research group used a number of other disease burden thresholds to define the target condition of the reference test for validation of mpMRI [22]. Therefore, we extracted the most commonly used definitions for data analysis.

#### 2.5. Data synthesis and analysis

The population studied in the literature showed considerable heterogeneity. To avoid some of these heterogeneities, we included only papers in which the mpMRI protocol (two functional MRI techniques) was applied according to the European Society of Urogenital Radiology (ESUR) guidelines [23,24]. The methodology for targeting the suspicious area on mpMRI at PB varied. We documented the PB methodology.

Data necessary to complete  $2 \times 2$  contingency tables were obtained from the studies regarding true positive, false positive, true negative, and false negative values. These data were used to calculate the sensitivity, specificity, negative predictive value, positive predictive value, and accuracy for each study.

We compared the rate of detection of significant disease among different PB approaches, because in almost all of the selected papers two or three different patients groups (PB-naïve, active surveillance, and prior negative TRUS PB) were compared rather than the targeted biopsy approaches. PB approaches consisted of visual TRUS biopsy, MRI/TRUS

fusion biopsy, in-bore MRI-guided biopsy, and transperineal template prostate mapping.

### 3. Evidence synthesis

The systematic literature search revealed 1729 records. The first step was to screen the titles and abstracts and remove duplicates, which yielded 525 potentially eligible studies that used MRI (Fig. 1). Another 188 studies were excluded because mpMRI was performed after PB, leaving 337 papers for full review. Of these 337 studies, 325 did not meet the inclusion criteria. Twelve studies were included for full analysis (Tables 1–6) [22,25–35]. The Cohen  $k$  value for inter-reviewer agreement was 0.82.

#### 3.1. Quality of the studies

Two independent reviewers evaluated the methodologic quality of all the studies. The quality of the studies varied. Five of the 12 studies were performed in a prospective manner [28,32–35]. Risk of bias regarding patient selection was low in two studies [22,29], whereas nine studies had a high risk of bias for patient selection [25–28,30–34]. The high risk was caused by unavailability of data on patient inclusion and exclusion. The risk of bias regarding the index test was low in seven studies and high in four studies. In two studies the risk of bias was unclear because information about blinding was not provided [30]. The risk of bias regarding the reference standard was low in three studies [22,26,33] and high in nine studies because the reference test varied and included targeted TRUS PB [27,31,32,34,35], in-bore MRI PB

**Table 1 – Patient characteristics**

Study (year)	Patients (n)	Patients with PCa (n)	Age (yr)		PSA (ng/ml)		Gleason score		Previous negative Bx (n)
			Median or mean	Range	Median or mean	Range	Median or mean	Range	
[25] (2014) <sup>a</sup>	129	141 <sup>b</sup>	62 (median)	41–82	5.8 (median)	1.2–20	NR	6–9	No
[26] (2014)	115	115	60.8 (mean)	NR	NR	4.1–10	NR	6–10	NR
[27] (2013)	105	36	65 (median)	59–70	7.5 (median)	5–11.2	NR	NR	Yes (105)
[28] (2014) <sup>a</sup>	54	34	64 (median)	39–75	10 (median)	2–23	NR	6–7	Yes (54)
[22] (2013) <sup>a</sup>	64	54	62 (mean)	40–76	8.2 (mean)	2.1–43	NR	6–7	Both (10)
[29] (2013) <sup>a</sup>	182	144	63.0 (mean)	NR	6.2 (median)	4.7–10	NR	6–7	Both (32)
[30] (2012)	265	108	66 (median)	61–69	11.4 (median)	8.6–18.3	NR	NR	Yes (265)
[31] (2013)	538	316	61.3 (mean)	NR	9.9 (mean)	NR	NR	6–NR	Yes (NR)
[32] (2011) <sup>a</sup>	114	68	63.6 (median)	41–83	13.4 (median)	0–228	NR	6–9	No
[33] (2014)	150	92	62.4 (median)	55–66.4	5.6 (median)	4.5–7.5	NR	NR	Both (18)
[34] (2014)	125	45	65	56.3–71	5.1	3.5–7.31	NR	6–9	Both (34)
[35] (2014)	140	91	66	59.5–72.4	9.7	5.2–10.9	NR	6–10	Yes (140)

PCa = prostate cancer; PSA = prostate-specific antigen; Bx = biopsy; NR = not reported.

<sup>a</sup> Publications from the same centre.

<sup>b</sup> The prostate was divided into two sectors.

[30], transperineal PB [22,25,27,29,33], and prostatectomy [26]. Readers interpreted the MRI examinations individually in 10 of the 12 studies, but only one of the studies reported interobserver variability (substantial agreement) [33]. The number of readers varied from one to five. Furthermore, readers were blinded to the clinical parameters in four studies, but had access to these parameters in five studies. Four studies used TRUS PB as a control group and compared targeted PB with 12-core systematic PB in the detection of significant PCa.

### 3.2. Characteristics of the studies

Patient characteristics are presented in Table 1. We were unable to ascertain how many unique patients were included in this study set because five studies originated from one centre. The patients had a median age of 62–65 yr (range

39–83 yr), a median PSA level of 5.1–13.4 ng/ml (range 1.2–228 ng/ml), and a Gleason score ranging from 6 to 10.

Of the 12 studies, 11 incorporated both DW-MRI and DCE, and one study also added MR spectroscopy for functional imaging (Table 2). Seven studies used non-endorectal MRI at both 1.5 and 3 T. Eleven out of 12 studies included high *b*-value acquisition ( $b \geq 1000$  s/mm<sup>2</sup>; Table 3). DCE-MRI was acquired with a minimum temporal resolution of 17 s for at least 4.30 min.

The study characteristics are presented in Table 4. Nine studies included men with at least one previous negative PB. The reference test showed considerable heterogeneity across studies. Four studies originating from the same research group used transperineal template prostate mapping, one study used transperineal fusion PB, one used TRUS-guided PB, four used MRI/TRUS fusion biopsy, one applied in-bore MR-guided biopsy, and one used definitive histology after RP.

**Table 2 – Technical characteristics of magnetic resonance imaging (MRI) equipment**

Study (year)	Field strength	MRI vendor	Coil	Lesions/patient, n (range)	Sequence used to define target
[25] (2014) <sup>a</sup>	1.5 T (n = 113) 3 T (n = 16)	Siemens Avanto (1.5 T) Philips Achieva (3 T)	PPA PPA	NR	T2 / DWI / DCE / high <i>b</i> value
[26] (2014)	3 T	Siemens Trio	ER	NR	T2 / DWI / DCE
[27] (2013)	3 T	Siemens Trio	ER	1.3 (1–3)	T2 / DWI / DCE
[28] (2014) <sup>a</sup>	1.5 T (n = 49) 3 T (n = 5)	Siemens Avanto (1.5 T) Philips Achieva (3 T)	PPA PPA	NR	T2 / DWI / DCE / high <i>b</i> value
[22] (2013) <sup>a</sup>	1.5 T	Siemens Avanto / Symphony	PPA	NR	T2 / DWI / DCE
[29] (2013) <sup>a</sup>	1.5 T 3 T	Siemens Avanto / Verio	PPA	NR	T2 / DWI / DCE / high <i>b</i> value
[30] (2012)	3 T	Siemens Trio / Skyra	PPA	1.4 (NR)	T2 / DWI / DCE / high <i>b</i> value
[31] (2013)	3 T	Philips Achieva	ER-PPA	NR	T2 / DWI / DCE / MRSI
[32] (2011) <sup>a</sup>	1.5 T	Siemens Avanto	PPA	NR	T2 / DWI / DCE / high <i>b</i> value
[33] (2014)	1.5 T (n = 70) 3 T (n = 80)	NR	PPA	NR	T2 / DWI / DCE / high <i>b</i> value
[34] (2014)	3 T	Siemens TRIO	PPA	1.4 (1–2)	T2 / DWI / DCE
[35] (2014)	3 T	Siemens Verio	ER-PPA	NR	T2 / DWI / DCE / high <i>b</i> value

PPA = pelvic phased-array coil; ER = endorectal coil; T2 = T2-weighted; DW = diffusion-weighted; DCE = dynamic contrast-enhanced; high *b* value = *b* value of >1000 s/mm<sup>2</sup>; MRSI = magnetic resonance spectroscopic imaging; NR = not reported.

<sup>a</sup> Publications from the same centre.

**Table 3 – Technical details of magnetic resonance imaging protocols**

Study (year)	Field strength (T)	T2-weighted magnetic resonance imaging			
		Slice orientation	Slice thickness, mm (gap)	FOV (mm)	Matrix
[25] (2014) <sup>a</sup>	1.5	Axial	3 (0.3)	180 × 180	320 × 310
	3	Coronal			
		Axial	3 (0.3)	200 × 200	320 × 310
		Coronal			
[26] (2014)	3	NR	–	–	–
[27] (2013)	3	3D	1.5 × 1.5 × 1.5 (0)	140 × 140	256 × 205
[28] (2014) <sup>a</sup>	1.5	Axial	3 (0.3)	180 × 180	256 × 256
		Coronal			
	3	NR	–	–	–
[22] (2013) <sup>a</sup>	1.5	Axial	3 (0.3)	260 × 260	192 × 192
		Coronal			
[29] (2013) <sup>a</sup>	1.5	Axial	3 (NR)	NR	NR
		Coronal			
	3	Axial	3 (NR)	NR	NR
		Coronal			
[30] (2012)	3	Three planes	3 (NR)	180 × 180 192 × 192	320 × 320 320 × 320
[31] (2013)	3	NR	–	–	–
[32] (2011) <sup>a</sup>	1.5	Axial	3 (0.3)	200	NR
[33] (2104)	1.5	Three planes	3 (NR)	NR	NR
	3	Axial	3 (NR)	NR	NR
[34] (2014)	3	Axial	NR	NR	NR

DWI						DCE			
Slice orientation	Slice thickness, mm (gap)	FOV (cm)	Matrix	<i>b</i> value (s/mm <sup>2</sup> )	High <i>b</i> value (s/mm <sup>2</sup> )	Slice orientation	FOV (mm)	Matrix	Temporal resolution
Axial	5 (0)	25 × 21	126 × 81	0, 100, 300, 800, 1000	2000	Axial	260 × 260	256 × 256	17 s (7 min)
Axial	5 (0)	25 × 21	126 × 81	0, 100, 300, 800, 1000	2000	Axial	250 × 250	256 × 256	15 s (5 min)
NR	–	–	–	–	–	NR	–	–	–
Axial	5 (1.65)	35 × 26	256 × 154	400, 800, 1000	NP	Axial	28 × 30	320 × 225	6.1 s (4.30 min)
NR	–	–	–	–	–	NR	–	–	–
Axial	3 (0)	26 × 26	192 × 192	0, 150, 500, 1000	–	Axial	26 × 26	192 × 192	17 s (9.59 min)
Axial	3 (NR)	NR	NR	0, 150, 500, 1000	1400–2000	Axial	NR	NR	<16 s (NR)
Axial	3 (NR)	NR	NR	0, 150, 500, 1000	1400–2000	Axial	NR	NR	<16 s (NR)
Axial	4 (NR)	26 × 26	128 × 128	0, 50, 500, 800	1400	Axial	23 × 23 19 × 19	180 × 180 128 × 128	2.5–3.5 s (NR)
NR	–	–	–	–	–	NR	–	–	–
Axial	5	26	NR	0, 150, 500, 1000	1400	Axial	26	NR	NR
Axial	4	NR	NR	0,400, 800	–	Axial	NR	NR	4–6 s (5 min)
Axial	4	NR	NR	0,400,800	1400	Axial	NR	NR	4–6 s (5 min)
Axial	NR	NR	NR	0, 50,500, 1000	1500, 2000	Axial	NR	NR	NR

FOV = field of view; NR = not reported; 3D = three-dimensional; DCE = dynamic contrast-enhanced; DWI = diffusion-weighted imaging.  
<sup>a</sup> Publications from the same centre.

All studies used a 5-point scale to score each MRI sequence. The Likert scoring system was applied in two studies [22,29] and the ESUR guidelines in five studies [25,28,33–35], whereas different criteria were applied for lesion definition in the remaining five studies. In five studies, all lesions were biopsied independently from the lesion score. Three studies biopsied lesion with a score of ≥3, whereas lesions with a score of ≥2 were biopsied in two studies. MR spectroscopy was used in one study [36]. The MRI criteria or final lesion definition for performing targeted PB were diverse, which may have influenced the outcome (Table 4). DW-MRI is a promising technique for evaluating aggressiveness because it can discriminate between significant and nonsignificant cancers in the peripheral zone [16,37].

**3.3. Detection of clinically significant disease**

Detection of clinically significant disease using mpMRI varied considerably among the studies (Table 5). The accuracy, sensitivity, and specificity ranges were 44–87%, 58–96%, and 23–87%, respectively. The ability of mpMRI to rule out significant disease (negative predictive value) improved with higher thresholds for the definition of clinically insignificant disease (Table 6) [22]. However, the positive predictive value decreased with increasing threshold for clinically significant disease. For example, a region of interest with cancer classified as positive on imaging might be classified as false-positive if the threshold is set slightly higher for the target condition [23]. The negative predictive value and positive predictive value for detection of clinically



**Table 4 – Study characteristics**

Study (year)	Prior prostate Bx	Reference test	Patient enrolment	Study design	Number of readers	Blinding	Region of interest	Scoring of mpMRI data			MRI criteria for Bx
								T2	DWI	DCE	
[25] (2014) <sup>a</sup>	Bx-naïve	TPM	NR	Retro	5 (ind)	Yes	WG	5PS	5PS	5PS	Score $\geq 3$
[26] (2014)	Bx proven	WMS	Consecutive	Retro	2 (con)	Yes	Index	NR	NR	NR	NR
[27] (2013)	Prior –Bx	Fusion Bx	NR	Retro	1	NR	Index	5PG	5PG	5PG	Grade $\geq 2$
[28] (2014) <sup>a</sup>	Prior –Bx	TPM	Consecutive	Pros	8 (ind)	Yes	WG	5PS	5PS	5PS	Score $\geq 3$
[22] (2013) <sup>a</sup>	Bx-naïve Prior –Bx Bx proven	TPM	NR	Retro	3 (ind)	No <sup>b</sup>	4 sectors	5PS	5PS	5PS	Score $\geq 3$
[29] (2013) <sup>a</sup>	Bx-naïve Prior –Bx Bx proven	TPM	Consecutive	Retro	4 (ind)	No	WG	5PS	5PS	5PS	NR
[30] (2012)	Prior –Bx	MR-Bx	Consecutive	Retro	2 (ind)	No	CSR	NR	NR	NR	DWI focal restriction + iso- or hyperintense signal on high <i>b</i> value
[31] (2013)	Bx-naïve	Fusion Bx	NR	NR	NR	Yes	Lesion	NR	NR	NR	All lesions included
[32] (2011) <sup>a</sup>	Prior –Bx	Targeted TRUS-Bx	Consecutive	Pros	1	No <sup>b</sup>	Sextants	Overall 5PS	Overall 5PS	Overall 5PS	All lesions included
[33] (2014)	Bx-naïve	Fusion TPM	NR	Pros	2 (ind)	No	18	5PS	5PS	5PS	All lesions included
[34] (2014)	Bx-naïve Prior –Bx Bx proven	Fusion Bx + 12-core TRUS-Bx	Consecutive	Pros	1	NR	Lesion	Overall 5PS	Overall 5PS	Overall 5PS	Score $\geq 2$
[35] (2014)	Prior –Bx	Fusion Bx + 12-core TRUS-Bx	Consecutive	Pros	3	NR	Lesion	5PS	5PS	5PS	Score $\geq 2$

mpMRI = multiparametric magnetic resonance imaging; TRUS = transrectal ultrasound; Bx = biopsy; –Bx = negative TRUS-guided Bx; TPM = transperineal template prostate mapping; NR = not reported; Retro = retrospective; Pros = prospective; WG = whole gland; WMS = whole-mount section histopathology; ind = independent; con = in consensus reading; index = index lesion; fusion Bx = MRI-US fusion biopsy; MR-Bx = magnetic resonance-guided Bx; CSR = cancer-suspicious region; T2 = T2-weighted; DW = diffusion-weighted; DCE = dynamic contrast-enhanced; 5PS = 5-point scale; 5PG = 5-point grade.

<sup>a</sup> Publications from the same centre.

<sup>b</sup> Blinded for biopsy results but not for clinical parameters.

**Table 5 – Performance characteristics of multiparametric magnetic resonance imaging for detection and ruling out of clinically significant cancer**

Study (year)	Patients	Overall cancer detection rate, n/N (%)	Reference	Analysis	Clinically significant disease								
					Accuracy, n/N (%)	TP (n)	TN (n)	FN (n)	FP (n)	Sens (%)	Spec (%)	PPV (%)	NPV (%)
[25] (2014) <sup>a</sup>	129	141/258 <sup>b</sup> (55)	Biopsy	Region	114/258 (44)	72	42	5	139	94	23	34	89
[26] (2014)	115	All	RP	Patient	75/104 (72)	52	23	2	27	96	46	66	92
[27] (2013)	105	36/105 (34)	Biopsy	Patient	24/48 (50)	NR	NR	NR	NR	NR	NR	NR	NR
[28] (2014) <sup>a,c</sup>	54	34/54 (63)	Biopsy	Region	57/108 (53)	26	31	8	43	76	42	38	79
[22] (2013) <sup>a,c</sup>	64	54/64 (84)	Biopsy	Region	183–201/256 (72–82)	41–51	132–154	20–30	29–53	58–73	71–84	49–63	84–89
[29] (2013) <sup>a</sup>	182	144/182 (79)	Biopsy	Patient	103/182 (57)	103	45	27	7	79	87	93	63
[30] (2012)	265	108/265 (41)	Biopsy	Patient	94/265 (35)	NR	NR	NR	NR	NR	NR	NR	NR
[31] (2013)	538	316/538 (59)	Biopsy	Patient	NR	NR	NR	NR	NR	94	28	38	91
[32] (2011) <sup>a</sup>	114	68/114 (60)	Biopsy	Region	217/252 (86)	64	153	3	32	95	84	68	98
[33] (2014)	150	92/150 (61)	Biopsy	Patient	49/150 (33)	49	49	2	50	96	50	50	96
[34] (2014)	125	45/125 (36)	Biopsy	Region	21/28 (75)	NR	NR	NR	NR	NR	NR	NR	NR
[35] (2014)	140	91/140 (65)	Biopsy	Region	67/140 (48)	NR	NR	NR	NR	NR	NR	NR	NR

RP = radical prostatectomy; TP = true positives; TN = true negatives; FN = false negatives; FP = false positives; Sens = sensitivity; Spec = specificity; PPV = positive predictive value; NPV = negative predictive value.

<sup>a</sup> Publications from the same centre.

<sup>b</sup> Prostate was divided in halves.

<sup>c</sup> University College London definition 2 used (Table 6).

**Table 6 – Definition of clinically significant disease**

Study (year)	Clinically significant disease
[25] (2014) <sup>a</sup>	UCL1 / UCL2 / Gleason 3 + 4 or higher / Gleason 4 + 3 or higher / CCL <sub>max</sub> ≥6 mm / CCL <sub>max</sub> ≥4 mm
[26] (2014)	Epstein criteria / Epstein criteria or ADC <850 μm <sup>2</sup> /s
[27] (2013)	Epstein criteria / UCL1 / UCL2 / Gleason score ≥7 / Gleason score ≥8
[28] (2014) <sup>a</sup>	UCL2
[22] (2013) <sup>a</sup>	UCL1 / UCL2
[29] (2013) <sup>a</sup>	UCL2
[30] (2012)	PSA >10 ng/ml, PSA density >0.15, clinical stage ≥T2b, Gleason 4 or 5, total CCL ≥10 mm
[31] (2013)	Gleason ≥7 / Gleason ≥8
[32] (2011) <sup>a</sup>	CCLI ≥3 mm and/or Gleason ≥7 / CCLI ≥5 mm and/or Gleason ≥7
[33] (2014) <sup>a</sup>	Gleason 7 with >5% Gleason 4 + either ≥30% of cores positive or Or Gleason 6–7 with ≤5% Gleason 4 + either ≥30% of cores positive or CCL <sub>max</sub> >8 mm
[34] (2014)	Gleason ≥7
[35] (2014)	Epstein criteria

ADC = apparent diffusion coefficient; CCL = cancer core length; CCL<sub>max</sub> = maximum CCL; Epstein criteria = Gleason score > 6, PSA >10 ng/ml, >3 biopsy cores positive, or at least one biopsy core with >50% involvement; UCL1 = University College London definition 1: Gleason ≥4 + 3 and/or CCL<sub>max</sub> ≥6 mm and/or total CCL ≥6 mm; UCL2 = UCL definition 2: Gleason ≥3 + 4 and/or CCL<sub>max</sub> ≥4 mm and/or total CCL ≥6 mm.

<sup>a</sup> Definition 4 was used.

<sup>a</sup> Publications from the same centre.

significant PCa ranged from 63% to 98% and from 34% to 68%, respectively. One study yielded high negative (98%) and positive (68%) predictive values, but patients were included with PSA up to 228 ng/ml (median 13.4 ng/ml), which may have introduced some selection bias [32]. Other potentially influential factors may be the selection of PB targets and the PB method. In three studies, all lesions were targeted with either visual or image fusion PB, whereas in four studies the entire prostate was sampled. This may have affected the positive predictive value; this can be illustrated by a lesion that is missed using mpMRI and is subsequently not sampled, whereas the lesion may have been found using template mapping.

### 3.4. Discussion

mpMRI of the prostate can detect clinically significant disease. The rate of detection of clinically significant disease ranged from 44% to 87%, which is higher than the rate reported for blind TRUS PB. According to our review findings, it is anticipated that MRI-targeted PB is two to three times better than the practice standard [38].

The ideal study design to address our research question would include mpMRI before PB and definitive pathology for whole-mount sections of RP specimens as the reference standard. However, such a study design is not applicable in clinical practice because of the costs, patient recruitment, and the use of RP as the gold standard. An alternative approach is to use transperineal template prostate mapping PBs. This technique has sufficiently high accuracy and may be the best available reference standard [39,40]. Transperineal template prostate mapping outperforms TRUS-guided PB, showing an average upgrading in 33% of patients and a change from unilateral to bilateral disease in more than 50% of patients [40]. Template prostate mapping detected more than 95% of lesions of ≥0.5 ml and the maximum cancer core length was ≥6 mm. This technique may provide an effective method for risk stratification of men with localised prostate cancer

[41]. Furthermore, a strategy of targeted PBs alone in prebiopsy MRI-suspicious areas is an attractive potential alternative to extended systematic PBs for detection of significant PCa [42]. However, the studies included only performed targeted PB of MRI-visible targets, which may have introduced a selection bias. Nevertheless, this approach may be used to select patients for PB because of the high negative predictive value. In the case of negative MRI, it remains unclear if much significant PCa is being missed by mpMRI. Transperineal prostate mapping has been used to overcome this uncertainty.

The accuracy for detection of clinical significant disease varied widely between studies (44–87%). Nonetheless, we did not observe any trends (other than the threshold for clinically significant PCa) across the study variables of biopsy method, study design, number of readers, scoring system, field strength and coil use, and PSA. This may be explained by the small number of studies currently available in the literature. For example, it is expected that 3 T (with an endorectal coil) should tend to yield better results than 1.5 T, but our systematic review did not identify evidence supporting this hypothesis.

Some limitations need to be discussed. First, only 12 papers were eligible for this standardised review and there was considerable heterogeneity among the studies included in terms of patient characteristics, MRI criteria for PB, reference standard, and biopsy status (PB-naïve and previous negative PB). Seven of the 12 studies used targeted PB with or without 12-core TRUS PB, which is limited compared to whole-mount section histopathology. Second, the MRI acquisition (temporal resolution for DCE-MRI and *b* values for DW-MRI) and technical parameters (coil type, field strength) differed among the studies. For example, use of a high *b*-value image is diagnostically superior to images acquired at *b* <1000 s/mm<sup>2</sup> for PCa detection [43]. There is some evidence that high *b* values (>1000 s/mm<sup>2</sup>) are better at detecting intermediate- or high-risk PCa compared to standard *b* values (50–1000 s/mm<sup>2</sup>) [44]. Third, the scoring

systems or image interpretations were not similar in all studies (Likert vs Prostate Imaging-reporting and Data System). Fourth, meta-analysis was not possible because of the wide heterogeneity across studies. Fifth, we did not categorise lesions in peripheral and transition zones because adequate information on this issue was not provided in any of the studies. Finally, the studies demonstrated diversity in the definition of clinical significance, which may have hampered comparison of outcome parameters. This makes it difficult to combine the results of such varied definitions for generalisation to clinical practice.

Nevertheless, our finding of a high negative predictive value for mpMRI is important for clinicians, because mpMRI could be used to rule out significant disease. This may result in fewer or no systematic or targeted PBs. Nevertheless, the negative predictive value may be affected to a greater extent than sensitivity and specificity in heterogeneous studies. DW-MRI is able to differentiate among low-, intermediate-, and high-grade cancer in the peripheral zone [17,37]. However, there is still considerable overlap among these groups using the apparent diffusion coefficient as a cutoff value. Further research is needed to optimise this sequence and to evaluate this technique for the detection of clinically significant PCa.

#### 4. Conclusions

mpMRI is able to detect significant PCa in biopsy-naïve males and men with prior negative biopsies. The high negative predictive value of mpMRI is important because mpMRI could be used to rule out significant disease. This may result in fewer or no systematic or targeted biopsies in patients with PSA suspicious for prostate cancer.

**Author contributions:** Jurgen Fütterer had full access to all the data in the study and takes responsibility for the integrity of the data and the accuracy of the data analysis.

**Study concept and design:** Briganti, De Visschere, Emberton, Giannarini, Kirkham, Thoeny, Villeirs, Fütterer, Villers.

**Acquisition of data:** Fütterer.

**Analysis and interpretation of data:** Fütterer, Giannarini.

**Drafting of the manuscript:** Fütterer, Giannarini.

**Critical revision of the manuscript for important intellectual content:** Briganti, De Visschere, Emberton, Giannarini, Kirkham, Thoeny, Villeirs, Fütterer, Villers.

**Statistical analysis:** Fütterer.

**Obtaining funding:** None.

**Administrative, technical, or material support:** None.

**Supervision:** Villers.

**Other:** None.

**Financial disclosures:** Jurgen Fütterer certifies that all conflicts of interest, including specific financial interests and relationships and affiliations relevant to the subject matter or materials discussed in the manuscript (eg, employment/affiliation, grants or funding, consultancies, honoraria, stock ownership or options, expert testimony, royalties, or patents filed, received, or pending), are the following: None.

**Funding/Support and role of the sponsor:** None.

**Acknowledgement statement:** Jurgen J. Fütterer, Alberto Briganti, Pieter De Visschere and Gianluca Giannarini are members of the Prostate Cancer Working Group of the European Association of Urology Young Academic Urologists.

#### References

- [1] Loeb S, Bjurlin MA, Nicholson J, et al. Overdiagnosis and overtreatment of prostate cancer. *Eur Urol* 2014;65:1046–55.
- [2] Hodge KK, McNeal JE, Terris MK, Stamey TA. Random systematic versus directed ultrasound guided transrectal core biopsies of the prostate. *J Urol* 1989;142:71–4.
- [3] Djavan B, Ravery V, Zlott A, et al. Prospective evaluation of prostate cancer detected on biopsies 1, 2, 3 and 4: when should we stop? *J Urol* 2001;166:1679–83.
- [4] Guichard G, Larré S, Gallina A, et al. Extended 21-sample needle biopsy protocol for diagnosis of prostate cancer in 1000 consecutive patients. *Eur Urol* 2007;52:430–5.
- [5] Moore CM, Robertson NL, Arsanious N, et al. Image-guided prostate biopsy using magnetic resonance imaging-derived targets: a systematic review. *Eur Urol* 2013;63:125–40.
- [6] Pinto PA, Chung PH, Rastinehad AR, et al. Magnetic resonance imaging/ultrasound fusion guided prostate biopsy improves cancer detection following transrectal ultrasound biopsy and correlates with multiparametric magnetic resonance imaging. *J Urol* 2011;186:1281–5.
- [7] Sciarra A, Panebianco V, Salciccia S, et al. Modern role of magnetic resonance and spectroscopy in the imaging of prostate cancer. *Urol Oncol* 2011;29:12–20.
- [8] Puech P, Sufana Iancu A, Renard B, Villers A, Lemaitre L. Detecting prostate cancer with MRI: why and how. *Diagn Interv Imaging* 2012;93:268–78.
- [9] Tamada T, Sone T, Higashi H, et al. Prostate cancer detection in patients with total serum prostate-specific antigen levels of 4–10 ng/mL: diagnostic efficacy of diffusion-weighted imaging, dynamic contrast-enhanced MRI, and T2-weighted imaging. *Am J Roentgenol* 2011;197:664–70.
- [10] Hoeks CM, Barentsz JO, Hambroek T, et al. Prostate cancer: multiparametric MR imaging for detection, localization, and staging. *Radiology* 2011;261:46–66.
- [11] Turkbey B, Pinto PA, Mani H, et al. Prostate cancer: value of multiparametric MR imaging at 3 T for detection—histopathologic correlation. *Radiology* 2010;255:89–99.
- [12] Delongchamps NB, Rouanne M, Flam T, et al. Multiparametric magnetic resonance imaging for the detection and localization of prostate cancer: combination of T2-weighted, dynamic contrast-enhanced and diffusion-weighted imaging. *BJU Int* 2011;107: 1411–8.
- [13] Delongchamps NB, Beuvon F, Eiss D, et al. Multiparametric MRI is helpful to predict tumor focality, stage, and size in patients diagnosed with unilateral low-risk prostate cancer. *Prostate Cancer Prostatic Dis* 2011;14:232–7.
- [14] Scheenen TW, Fütterer J, Weiland E, et al. Discriminating cancer from noncancer tissue in the prostate by 3-dimensional proton magnetic resonance spectroscopic imaging: a prospective multicenter validation study. *Invest Radiol* 2011;46:25–33.
- [15] Donati OF, Mazaheri Y, Afaq A, et al. Prostate cancer aggressiveness: assessment with whole-lesion histogram analysis of the apparent diffusion coefficient. *Radiology* 2014;271:143–52.
- [16] Kobus T, Hambroek T, Hulsbergen-van de Kaa CA, et al. In vivo assessment of prostate cancer aggressiveness using magnetic resonance spectroscopic imaging at 3 T with an endorectal coil. *Eur Urol* 2011;60:1074–80.
- [17] Turkbey B, Choyke PL. Multiparametric MRI and prostate cancer diagnosis and risk stratification. *Curr Opin Urol* 2012;22:310–5.



- [18] Peng Y, Jiang Y, Yang C, et al. Quantitative analysis of multiparametric prostate MR images: differentiation between prostate cancer and normal tissue and correlation with Gleason score—a computer-aided diagnosis development study. *Radiology* 2013; 267:787–96.
- [19] Liberati A, Altman DG, Tetzlaff J, et al. The PRISMA statement for reporting systematic reviews and meta-analyses of studies that evaluate health care interventions: explanation and elaboration. *Ann Intern Med* 2009;151:W65–94.
- [20] Whiting PF, Rutjes AW, Westwood ME, et al. QUADAS-2: a revised tool for the quality assessment of diagnostic accuracy studies. *Ann Intern Med* 2011;155:529–36.
- [21] Moore CM, Kasivisvanathan V, Eggener S, et al. Standards of reporting for MRI-targeted biopsy studies (START) of the prostate: recommendations from an international working group. *Eur Urol* 2013; 64:544–52.
- [22] Arumainayagam N, Ahmed HU, Moore CM, et al. Multiparametric MR imaging for detection of clinically significant prostate cancer: a validation cohort study with transperineal template prostate mapping as the reference standard. *Radiology* 2013;268:761–9.
- [23] Barentsz JO, Richenberg J, Clements R, et al. ESUR prostate MR guidelines 2012. *Eur Radiol* 2012;22:746–57.
- [24] de Rooij M, Hamoen EH, Fütterer JJ, Barentsz JO, Rovers MM. Accuracy of multiparametric MRI for prostate cancer detection: a meta-analysis. *Am J Roentgenol* 2014;202:343–51.
- [25] Abd-Alazez M, Kirkham A, Ahmed HU, et al. Performance of multiparametric MRI in men at risk of prostate cancer before the first biopsy: a paired validating cohort study using template prostate mapping biopsies as the reference standard. *Prostate Cancer Prostatic Dis* 2014;17:40–6.
- [26] Chamie K, Sonn GA, Finley DS, et al. The role of magnetic resonance imaging in delineating clinically significant prostate cancer. *Urology* 2014;83:369–75.
- [27] Sonn GA, Chang E, Natarajan S, et al. Value of targeted prostate biopsy using magnetic resonance-ultrasound fusion in men with prior negative biopsy and elevated prostate-specific antigen. *Eur Urol* 2014;65:809–15.
- [28] Abd-Alazez M, Ahmed HU, Arya M, et al. The accuracy of multiparametric MRI in men with negative biopsy and elevated PSA level—can it rule out clinically significant prostate cancer? *Urol Oncol* 2014;32, 45:e17–22.
- [29] Kasivisvanathan V, Dufour R, Moore CM, et al. Transperineal magnetic resonance image targeted prostate biopsy versus transperineal template prostate biopsy in the detection of clinically significant prostate cancer. *J Urol* 2013;189:860–6.
- [30] Hoeks CMA, Schouten MG, Bomers JGR, et al. Three-Tesla magnetic resonance-guided prostate biopsy in men with increased prostate-specific antigen and repeated, negative, random, systematic, transrectal ultrasound biopsies: detection of clinically significant prostate cancers. *Eur Urol* 2012;62:902–9.
- [31] Rais-Bahrami S, Siddiqui MM, Turkbey B, et al. Utility of multiparametric magnetic resonance imaging suspicion levels for detecting prostate cancer. *J Urol* 2013;190:1721–7.
- [32] Rouse P, Shaw G, Ahmed HU, Freeman A, Allen C, Emberton M. Multi-parametric magnetic resonance imaging to rule-in and rule-out clinically important prostate cancer in men at risk: a cohort study. *Urol Int* 2011;87:49–53.
- [33] Thompson JE, Moses D, Shnier R, et al. Multiparametric magnetic resonance imaging guided diagnostic biopsy detects significant prostate cancer and could reduce unnecessary biopsies and over detection: a prospective study. *J Urol* 2014;192:67–74.
- [34] Wysock JS, Rosenkrantz AB, Huang WC, et al. A prospective, blinded comparison of magnetic resonance (MR) imaging-ultrasound fusion and visual estimation in the performance of MR-targeted prostate biopsy: the PROFUS trial. *Eur Urol* 2014;66:343–51.
- [35] Salami SS, Ben-Levi E, Yaskiv O, et al. In patients with a previous negative prostate biopsy and a suspicious lesion on MRI, is a 12-core biopsy still necessary in addition to a targeted biopsy? *BJU Int*. In press. <http://dx.doi.org/10.1111/bju.12938>
- [36] Dickinson L, Ahmed HU, Allen C, et al. Magnetic resonance imaging for the detection, localisation, and characterisation of prostate cancer: recommendations from a European consensus meeting. *Eur Urol* 2011;59:477–94.
- [37] Hambroek T, Hoeks C, Hulsbergen-van de Kaa C, et al. Prospective assessment of prostate cancer aggressiveness using 3-T diffusion-weighted magnetic resonance imaging-guided biopsies versus a systematic 10-core transrectal ultrasound prostate biopsy cohort. *Eur Urol* 2012;61:177–84.
- [38] Pokorny MR, de Rooij M, Duncan E, et al. Prospective study of diagnostic accuracy comparing prostate cancer detection by transrectal ultrasound-guided biopsy versus magnetic resonance (MR) imaging with subsequent MR-guided biopsy in men without previous prostate biopsies. *Eur Urol* 2014;66:22–9.
- [39] Barqawi AB, Rove KO, Gholizadeh S, O'Donnell CI, Koul H, Crawford ED. The role of 3-dimensional mapping biopsy in decision making for treatment of apparent early stage prostate cancer. *J Urol* 2011; 186:80–5.
- [40] Taira AV, Merrick GS, Galbreath RW, et al. Performance of transperineal template-guided mapping biopsy in detecting prostate cancer in the initial and repeat biopsy setting. *Prostate Cancer Prostatic Dis* 2010;13:71–7.
- [41] Ahmed HU, Hu Y, Carter T, et al. Characterizing clinically significant prostate cancer using template prostate mapping biopsy. *J Urol* 2011;186:458–64.
- [42] Haffner J, Lemaître L, Puech P, et al. Role of magnetic resonance imaging before initial biopsy: comparison of magnetic resonance imaging-targeted and systematic biopsy for significant prostate cancer detection. *BJU Int* 2011;108:E171–8.
- [43] Tamada T, Kanomata N, Sone T, et al. High b value (2,000 s/mm<sup>2</sup>) diffusion-weighted magnetic resonance imaging in prostate cancer at 3 Tesla: comparison with 1,000 s/mm<sup>2</sup> for tumor conspicuity and discrimination of aggressiveness. *PLoS One* 2014;9:e96619.
- [44] Ueno Y, Kitajima K, Sugimura K, et al. Ultra-high b-value diffusion-weighted MRI for the detection of prostate cancer with 3-T MRI. *J Magn Reson Imaging* 2013;38:154–60.