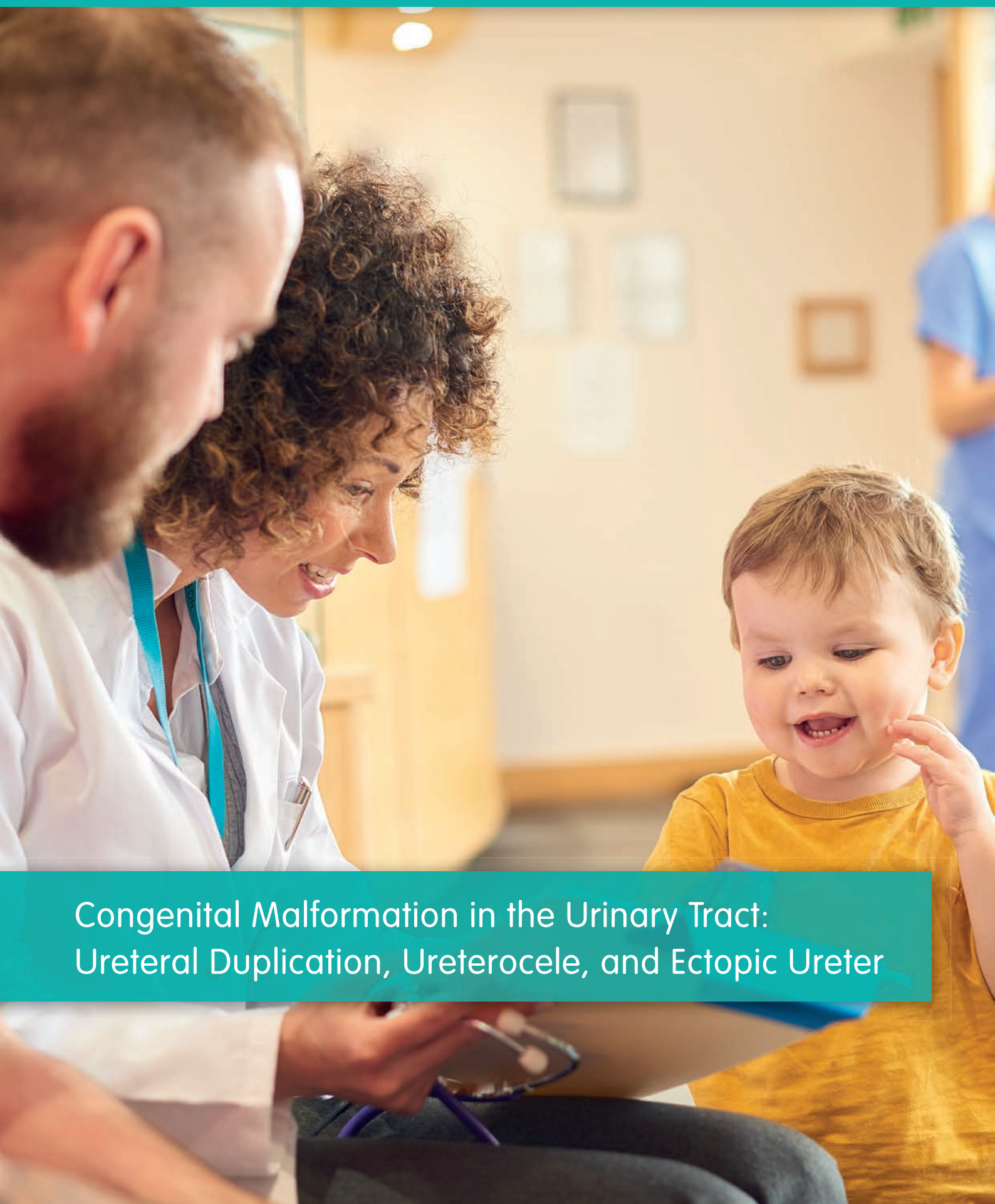



Congenital Malformation in the Urinary Tract:
Ureteral Duplication, Ureterocele, and Ectopic Ureter

Table of contents

Ureteral Duplication	3
Symptoms and Diagnosis	3
Treatment	3
Ureterocele	3
Symptoms and Diagnosis	3
Treatment	4
Ectopic Ureter	4
Symptoms and Diagnosis	4
Treatment	5
Treatment Overview	5
Glossary	6

This leaflet contains general information about renal duplication. If you have any specific questions you should consult your doctor or other professional healthcare provider.

This information was produced by the European Association of Urology (EAU) Patient Information Working Group.

Dr. Michele Innocenzi Rome (IT)
Dr. Martin Kubát Prague (CZ)
Dr. Antonin Prouza Prague (CZ)

This information was updated by the EAU Patient Information Working Group, January 2020.

You can find this and other information on urological diseases at our website: <http://patients.uroweb.org>

Congenital Malformation in the Urinary Tract: Ureteral Duplication, Ureterocele, and Ectopic Ureter

Development of the urinary organs before birth prepares the body to void urine. Sometimes those organs do not develop correctly, perhaps because of heredity or related to an unknown influence. The result is different anatomy that exists at birth—called congenital malformation.

Congenital malformations of the urinary tract include:

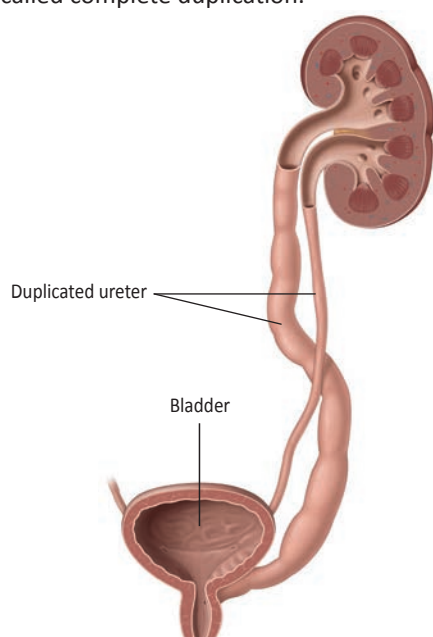
- Ureteral duplication
- Ureterocele
- Ectopic ureter

These conditions will be defined and discussed here.

Ureteral Duplication

One of the most common malformations of the urinary tract is ureteral duplication. The ureter is the tube that carries urine from a kidney to the bladder. Typically, each kidney has one ureter. In ureteral duplication, however, a kidney has two ureters connecting it to the bladder. This condition is also called a duplicated or duplex collecting system.

Sometimes two ureters may leave the kidney but join into a single tube before arrival at the bladder. This is called incomplete duplication. When the ureters are entirely separate throughout the course to the bladder (**Figure 1**), it is called complete duplication.



© 2018 patients.uroweb ALL RIGHTS RESERVED

Fig. 1: Ureteral duplication: anatomy of a duplicated collecting system.

Symptoms and Diagnosis

Despite an extra ureter, a duplicated collecting system can slow the flow of urine, causing urinary obstruction. It is also associated with vesicoureteral reflux (when urine flows backward from the bladder into the ureter toward the kidney), ureterocele and ectopic ureter.

Ureteral duplication is sometimes noticed on routine ultrasound during pregnancy. After birth, symptoms may lead to diagnosis. However, in the majority of the children with ureteral duplication, no symptoms exist.

Treatment

Deciding on treatment depends on multiple factors. A conservative approach should always be the first choice whenever possible (see Treatment Overview).

Ureterocele

Ureterocele (pronounced “u-ree-tero-seel”) is a pouch-like enlargement of the ureter at the end where it connects to the bladder. This enlargement usually interferes with the flow of urine. Most patients with ureterocele also have a duplicated collecting system. Girls are more likely to be affected.

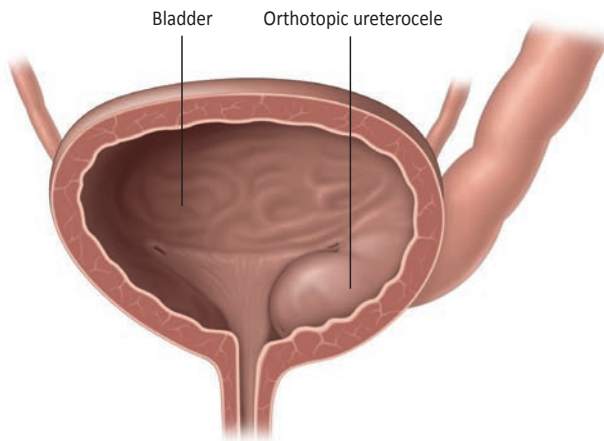
There are two types of ureterocele (**Figures 2a and b**):

- **Orthotopic ureterocele:** the pouch-like blockage is located completely inside the bladder.
- **Ectopic ureterocele:** the pouch-like blockage extends into the bladder opening or the urethra. This is the most common form.

Ureterocele usually obstructs the flow of urine into the urethra, the tube that carries urine out of the body. The degree of obstruction varies based on the type of ureterocele and the amount of abnormal tissue development. Ectopic ureterocele is more serious because the bladder opening to the urethra does not work properly.

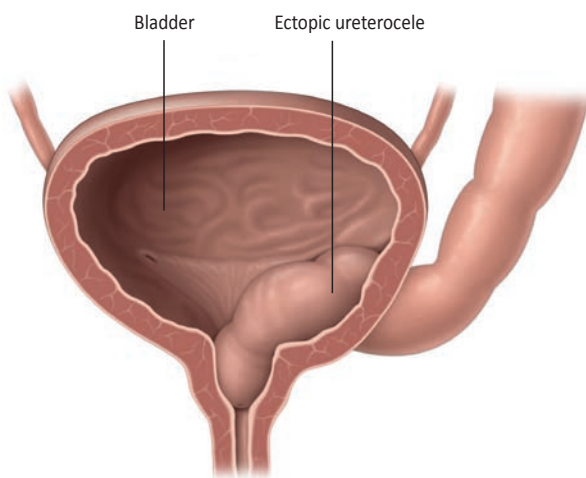
Symptoms and Diagnosis

Ureterocele symptoms may be noted before or after birth. Ultrasound during pregnancy may show an obstructive ureterocele. If ureterocele is seen on ultrasound before



© 2018 patients.uroweb ALL RIGHTS RESERVED

Figure 2a: Orthotopic ureterocele.



© 2018 patients.uroweb ALL RIGHTS RESERVED

Figure 2b: Ectopic ureterocele.

birth, the doctor will repeat the ultrasound to confirm the diagnosis. If ureterocele and a duplicated collecting system are confirmed, the doctor will do further tests to look at kidney function.

Symptoms soon after birth can lead to diagnosis in infants. In girls, the doctor may see a ureterocele in the opening of the urethra at birth. Newborn boys may not be able to pass urine. The kidneys may also be inflamed.

Symptoms that might occur later include bladder inflammation, difficulty urinating, and urgent need to urinate. Sometimes urine will flow backward from the bladder into the ureter (toward the kidney) in patients with ureterocele. This condition is called vesicoureteral reflux. Urine flows back into the ureter on the same side as the blockage or into the ureter opposite the blockage.

Treatment

In most children showing no symptoms (asymptomatic), treatment is not needed and follow-up is recommended. Urinary tract infections are treated with antibiotics, if present. In addition, further tests should be done using x-ray to assess kidney function. If kidney function is good, the ureterocele can be treated using endoscopic decompression. If kidney function is not good, some of the kidney tissue may be removed surgically. This operation is called partial nephrectomy.

Endoscopic decompression of ureterocele

If the upper part of the kidney is working, the ureterocele can be punctured to decompress the pouch-like enlargement blocking the urinary flow. This procedure is called endoscopic decompression. It is performed inside the body through a tube like surgical instrument called an endoscope. The urologist uses a laser through the endoscope to puncture the ureterocele. This reduces the size of the blockage and helps urine flow. This treatment sometimes causes the urine to flow backward from the bladder into the ureter (vesicoureteral reflux). This should be treated.

Partial nephrectomy

If the kidney is not working well, surgery may be needed to remove the non-working part.

Ectopic Ureter

An ectopic ureter connects the kidney to a site other than the bladder. This occurs less frequently than ureterocele and is more common in girls. Some patients do not have symptoms, so it can be difficult to tell how often this occurs. Most patients with an ectopic ureter also have complete duplication of the ureter.

The typical locations of ectopic ureters are different in boys and girls:

- In boys, the ectopic ureter never ends below the external sphincter. It often runs from the kidney to the urethra, near the prostate, or near the glands that produce semen.
- In girls, the ureteral opening may be located in the urethra, in the vaginal opening, in the vagina, or in the uterus or fallopian tubes.

Symptoms and Diagnosis

Different symptoms may appear depending on the child's age and sex:

- In newborns, parents may see pus in the urine (pyuria) or suspect a urinary infection.

- In young girls, parents may see a loss of urine after normal voiding, the presence of urine in the vagina, or another opening for passing urine located near the urethra.
- Preadolescent boys usually have inflammation of the tube that stores and carries sperm (epididymitis) and swollen seminal glands in the pelvis.

What is a UTI?

A urinary tract infection (UTI) is an infection in any part of the urinary system — the kidneys, ureters, bladder and urethra. Most infections involve the lower urinary tract — the bladder and the urethra. Girls have a higher likelihood of having UTI than boys. Two thirds of young children with UTI accompanied by fever will have an infection involving the kidneys. About 15 percent of these cases will develop permanent kidney scars. Kidney scarring can lead to high blood pressure, complications during pregnancy, and kidney failure. Therefore, early and accurate diagnosis and treatment are essential to prevent kidney scarring.

UTI symptoms

The symptoms of UTI are not always obvious because young children may not be able to describe how they feel. Fever may be the only apparent symptom of a UTI. Infants and young children may experience fever, irritability, foul smelling urine, or vomiting. Older children may experience fever and may complain of pain or stinging while urinating, or have abdominal or back pain. They may also experience more frequent urination, wetting problems, cloudy, bloody, or foul-smelling urine.

Source: Children's Hospital of Pittsburgh

If symptoms are noted, the doctor should test if urine flows backward from the bladder into the ureter (vesicoureteral reflux). In addition, the doctor will test kidney function (DMSA renal kidney scan) to determine whether the area drained by the ectopic ureter is affected. Magnetic resonance urography or high-resolution MRI could be used to study the entire urinary tract.

Treatment

Ectopic ureter is treated:

- If urine flows backward from the bladder into the ureter.
- If symptoms occur, such as urinary tract infection, pus in the urine, or kidney inflammation.
- If the upper part of the kidney is not working.

If the kidney is not working well, the doctor may need to perform a partial nephrectomy to remove the nonworking part.

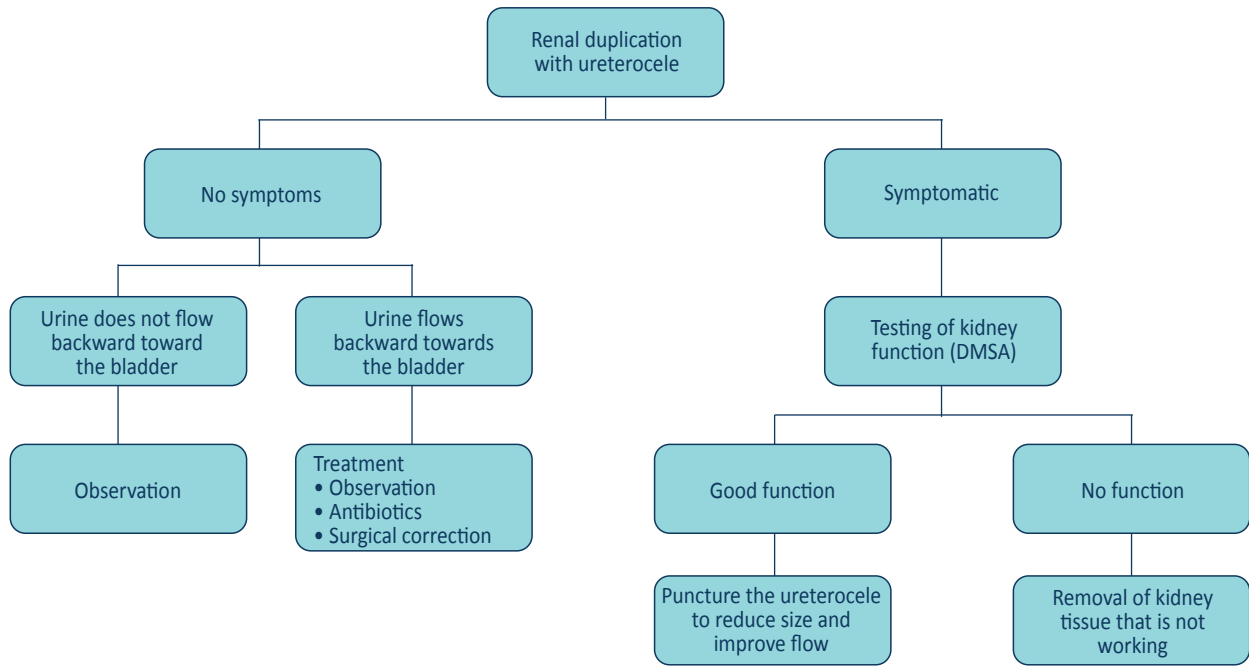
Treatment Overview

If symptoms are mild, the doctor might prefer to monitor the condition and treat symptoms such as urinary tract infection and backward flow of urine. Surgical treatments include endoscopic decompression and partial nephrectomy. Choice of treatment depends on the patient's condition:

- Patient age
- Overall health
- Kidney function
- Problems with urine flow
- Blockage of urine by a ureterocele
- Parents' and surgeon's preferences

Diagnosis	Definition	Treatment
Ureteral duplication	A kidney has two ureters connecting it to the bladder instead of one	<ul style="list-style-type: none"> • Monitoring and treatment of symptoms if mild
Ureterocele	A pouch-like enlargement of the ureter at the end where it connects to the bladder	<ul style="list-style-type: none"> • Endoscopic decompression to puncture the ureterocele surgically, which reduces its size and unblocks urinary flow • Partial nephrectomy to remove non-working tissue from the kidney
Ectopic ureter	A ureter that connects the kidney to a site other than the bladder—for example, to the urethra or the vagina	<ul style="list-style-type: none"> • Partial nephrectomy to remove non-working tissue from the kidney • Surgical reconstruction of the urinary organs

* The underlined terms are listed in the glossary.



EAU ©2018 patients.uroweb ALL RIGHTS RESERVED

Fig. 3: Treatment decision making for congenital malformations in the urinary tract.

Glossary of terms

Complete duplication

Ureters are entirely separate throughout the course to the bladder

Congenital malformation

Different anatomy that exists at birth

Duplicated or duplex collecting system

Other names for ureteral duplication

Ectopic ureter

A ureter that connects the kidney to a site other than the bladder

Ectopic ureterocele

A pouch-like blockage that extends into the bladder opening or the urethra

Endoscopic decompression

Surgical puncture of a ureterocele to decompress the pouch-like enlargement blocking the urinary flow

Epididymitis

Inflammation of the tube that stores and carries sperm

Fallopian tubes

A female reproductive organ that allows eggs to travel from the ovaries to the uterus

Orthotopic ureterocele

The pouch-like blockage is located completely inside the bladder

Partial nephrectomy

Surgical removal of part of a kidney

Pyuria

Pus in the urine

Ureter

Tube that carries urine from a kidney to the bladder

Ureteral duplication

A kidney has two ureters connecting it to the bladder

Ureterocele

A pouch-like enlargement of the ureter at the end where it connects to the bladder

Urethra

The tube that carries urine out of the body

Urinary obstruction

Blocking of the flow of urine

Urologist

A doctor specialised in health and diseases of the urinary tract and the genitals

Vesicoureteral reflux

Urine flows backward from the bladder into the ureter (toward the kidney)

European Association of Urology

PO Box 30016

NL-6803 AA ARNHEM

The Netherlands

e-Mail: info.patientinformation@uroweb.org

Website: patients.uroweb.org